

Hoof Capability of Barefoot-Kept Horses and Ponies Walking Over Artificial Environments: An Anatomical and Radiological Study

Sarah Albanozzo^{1*}, Louis Borg², Liberato Camilleri³ and Robert M Bowker⁴

¹90, Triq Windsor, Sliema, SLM 1852, Malta

²128, Valley Road, Birkirkara, Malta

³Statistics and Operations Research, Faculty of Science, University of Malta, MSD 2050 Msida, Malta

⁴Department of Pathobiology and Diagnostic Investigation, Michigan State University, East Lansing, Michigan, U.S.A.

*Corresponding Author: Sarah Albanozzo, 90, Triq Windsor, Sliema, SLM 1852, Malta.

Received: March 14, 2024; Published: April 11, 2024

Abstract

Hoof capability of domesticated, barefoot-kept horses and ponies traversing artificial environments remains undocumented. In this study, four equines were walked in-hand for 16 days, covering a distance of 50 km, over three solid surfaces. Subsequently, we conducted an assessment of hoof morphology. Hooves (n = 16) were radiographed before and after the trial, spaced 3 weeks apart, for sole depth measurement. External measurements of feet were recorded 24 hours before day 1 and repeated on days 9, 10 and 18. Radiographs revealed increased sole depth in 11 hooves, notably at the palmar process, and some misalignment in certain phalanges. On day 9, after a 36-km distance, all hooves exhibited calloused soles and frogs, and required trimming. The front hooves of the horses had a pronounced, natural concavity. Hard surfaces were found to stimulate sole growth, with a portion of sole thickness preferentially accumulating within the dermal zone. Collectively, the maintenance of short trimming cycles to prevent misalignment, minimize hoof-wall loading and maintain a load-sharing system, may be necessary for barefoot-kept horses considering their rapid growth rate.

Keywords: Radiographs; Horses; Ponies; Barefoot Hooves; Sole Depth; Forage

Introduction

Adequate sole depth in the hooves of domesticated, barefoot-kept horses is essential for locomotion. In healthy equine feet, the sole cushions protect the distal phalanx [1] and are typically thicker caudally [2]. Although there is no standardized sole depth for individual barefoot-kept breeds, conflicting information exists regarding the optimal internal thickness, ranging between 10 - 15 mm [3-5]. Nonetheless, Mellish, *et al.* [6] conducted a study on cadaver hooves from feral horses in Canada and observed shallow soles, with 65% having less than 11 mm at the toe. Sole depth at the palmar process (PP) was similar, revealing negative palmar angles. These herds resided on soft substrate, yet remained sound, indicating sole adaptation [6]. Feral horses in New Zealand presented similar results, displaying hoof morphology adapted to their soft environments [7]. Radiographic imaging of the soles of live animals, including both the vascular dermis and the thicker keratinized epidermis, does not consider possible preferential contributions of these tissue elements to foot health and soundness.

Understanding the mechanical and biological properties of the equine foot is crucial for comprehending sole function and growth. Trimming methods that distribute impact forces between the hoof wall, sole and frog to the appropriate internal foot tissues, are essential for achieving efficient and correct biomechanics for locomotion [4,8]. Horses with some degree of long toes and varying underrun heels, while considered sound, may not have healthy feet [9]. This hoof shape is typical of navicular cases [10]. Although the hoof can twist, torque, flex, and expand under varying impact and loading forces over uneven ground surfaces [8,11], its capability to correctly process these energy waves minimizes foot pathologies. The somatosensory system detects and responds to such forces, becoming an important contributor to sole responses, including growth. Foot receptors were mapped within the hoof 30 years ago, illustrating their potential neurophysiological roles in movement [12]. However, their potential involvement in other solar actions, particularly in guiding and modulating energy waveforms through various foot tissues, vascular perfusion, and even foot growth on hard surfaces, has never been explored. This neuroanatomical system, rich in receptors allowing the foot to obtain information from the terrain on which it moves [13], senses specific sensations, including pressure, vibration, balance, pain, and temperature, all of which contribute directly and indirectly to the overall internal health of the foot [13]. Particular fast-adapting receptors known as Pacinian corpuscles (or FA2 receptors), mainly located caudally, respond to pressure and vibration, contributing to increased perfusion of matrix tissues, to enhance sole growth [13]. In habitually barefoot human populations, thicker soles are evident at the footpad [14], owing to a large cluster of FA2s at this site [15].

Diet and management are critical factors affecting sole health. A high sugar-starch diet based on grains and concentrated feed, prolonged periods of grazing on lush grass, and obesity, can cause metabolic issues, leading to laminitis or founder [16,17]. Very thin soles are often associated with this pathology, which can eventually immobilize the horses [9,17]. Unhygienic housing conditions that confine horses to standing in their urine and manure for extended periods or muddy environments can also lead to sole tenderness and thrush [4,18].

Internal sole measurements, including the positions of the phalanges, palmar and plantar angles of the distal phalanx and mediolateral imbalance [19], can be confirmed through radiographs [3,4,20].

Recent studies emphasize the health benefits of unshod horse hooves [21-24], with an increasing number of horse owners choosing barefoot options [25,26]. To the best of our knowledge, sole thickness in hooves of domesticated, barefoot-kept horses walking over hard, artificial environments has not been reported in equine veterinary literature. Although nineteenth-century literature offers insights into the capabilities of hooves of barefoot-kept horses ridden or driven over dirt and cobbled roads [27,28], prior to the introduction of tarmac [29], none of these studies measured sole depth.

In this study, we aimed to use completely forage-fed barefoot-kept equines with a 24/7 turnout and radiographically measure the sole depth, including the external morphological characteristics of their hooves, in response to three abrasive surfaces (30 km tarmac, 8 km concrete screed, and 12 km limestone gravel). As only cadaveric specimens have been used to assess the morphological characteristics of this solar area to date, we hypothesised that by the end of this study, the (hoof) soles would become hard (calloused), sole depths would decrease by a few millimetres and hoof walls would require trimming.

Materials and Methods

Horses and ponies

The experimental procedure was conducted in accordance with Maltese law on animal care [30], ensuring non-invasive and non-harmful data collection. A qualified equine veterinarian conducted pre- and post-study clinical examinations on four animals, comprising three adult geldings and one adult mare. These equines had healthy feet, lived outdoors with open shelters, navigating various terrains in a 3,000m² area of terraced fields. The horses included a Standardbred and a Thoroughbred weighing 550 kg ± 50 kg, and two Shetland

ponies (one mare) weighing $200 \text{ kg} \pm 20 \text{ kg}$. Their ages ranged from 8 - 20 years (mean age: 14 years), and average body condition score was 6 (on a scale of 1 - 9). Varied characteristics such as breed, age, and sex were intentionally chosen to improve reproducibility. Both horses and ponies were routinely trimmed every 2 - 3 weeks and were maintained barefoot. No visible, interrupted growth rings, flares on the outer hoof capsules, or pathologies on the frogs and soles were observed, prior to the study. The Standardbred had his shoes removed six years ago, whereas the others were never shod. Each horse received a daily diet of 10 - 12 kg of hay, coupled with a forage balancer consisting of 100g Forageplus®, 600g Dengie Alfa-A® and 300g Speedi-Beet® DW (fed soaked). The ponies were fed a quarter of the amount provided to the horses, with a balancer dose of 40g.

Data collection

The horses and ponies were initially walked for nine consecutive days (4 km per day), were trimmed, and rested for two days. Subsequently, they resumed walking (2 km per day) for another seven consecutive days. A day before the experiment, all equine hooves were radiographed in the latero-medial projection, at a distance of 60 cm (Figure 1), to ensure adequate sole depth and improve phalangeal alignment, where necessary. Radiographs and sole measurements were obtained using a GIERTH HK 80/15 Multimage PLUS (Multimage S.R.L., VA, Italy) and Canon CXDI-801C Wireless digital radiography system (MXR, San Diego, CA, USA). Sole depths were measured at two anatomical sites of the coffin bone: from the tip of the distal border (crena) and from the angle (palmar process). A Precision hoof pick and Mr. Pen Stainless Steel ruler were used for the external measurements of each hoof. Based on a previous trial, measurements were documented from the solar side 24 hours prior to day 1, and repeated on days 9, 10 and 18, to monitor hoof growth: (a) distance from frog apex-toe, (b) collateral groove (CG) depth at mid-bar, (c) CG depth at apex, (d) heel height, and (e) frog width. The dorsal side included (f) coronet-toe distance. Radiographs of all hooves were repeated at the end of the study on day 21.

Photographs of soles were captured with an iPhone 11 after each walk, to check for pathologies and to monitor hoof wall growth. A GoPro (HERO11 Black) was used to record all walks, and an iPhone 11 GPS Tracker (MapMyWalk App) documented distances in kilometres.



Figure 1: Latero-medial projection of the left front hoof.

Statistical analysis

Shapiro-Wilk tests were used to determine the normality or skewness of the thickness distribution of the hoof sole. The null hypothesis, indicating normal distribution, was accepted when the p-value exceeded 0.05. The alternative hypothesis denoted a skewed thickness distribution and was accepted when the p-value was less than 0.05. Paired samples t-tests were used to compare the mean sole thickness

before and after the 16-day 50 km walk intervention. This analysis was performed individually for horses and ponies. The null hypothesis, indicating marginal variation in mean sole thickness between phases, was accepted when the p-value exceeded 0.05.

Results

Internal measurements

A consistent growth pattern was observed in the soles of most hooves during follow-up radiographs. Eleven soles across all four equines thickened at one or both anatomical sites, with a significant increase visible at the PP (Figure 2), following the 50 km distance on abrasive surfaces. Phalanges lost alignment in four hooves, two of which are depicted in figure 2. Notably, three soles remained unchanged and two experienced a minor reduction of a few millimeters each, at one or both anatomical sites. The Standardbred exhibited a negative palmar angle in the left hind (LH) hoof, with a sole depth of 19 mm at the crena and 14 mm at the PP. Follow-up radiographs of this limb revealed arthritis in the hock (Figure 3 and 4).

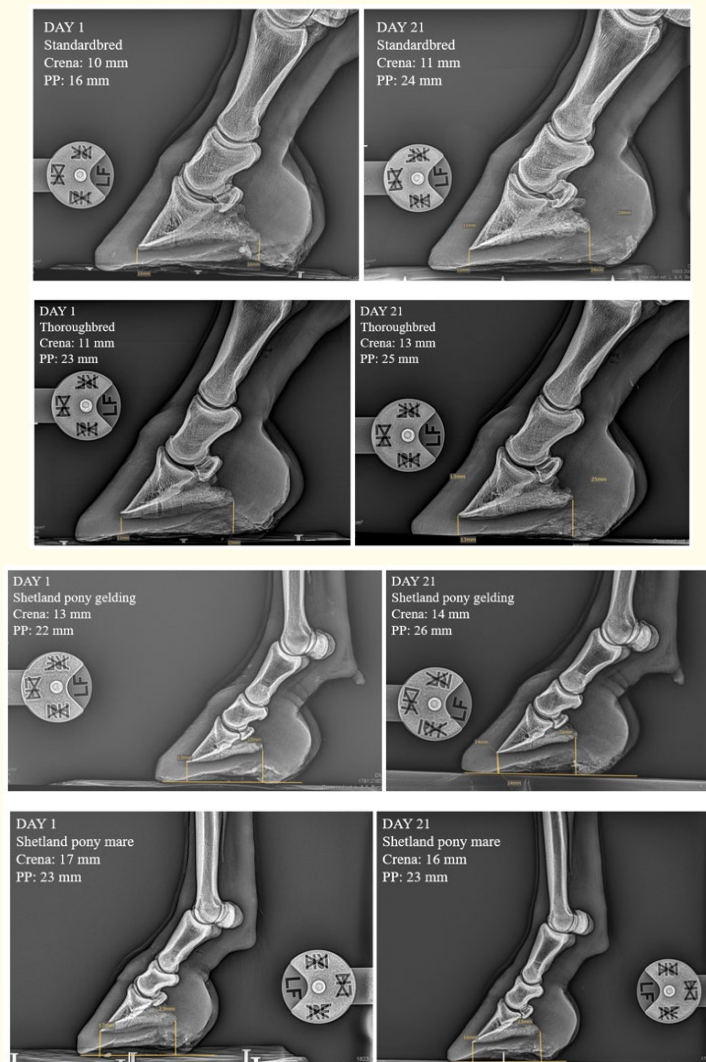


Figure 2: Radiographs (lateral view) of the left front with measurements of the sole depth.

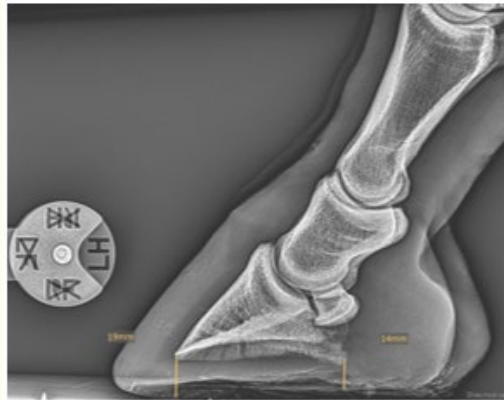


Figure 3: Follow up radiograph of the Standardbred displaying a negative plantar angle of the distal phalanx in the left hind hoof.

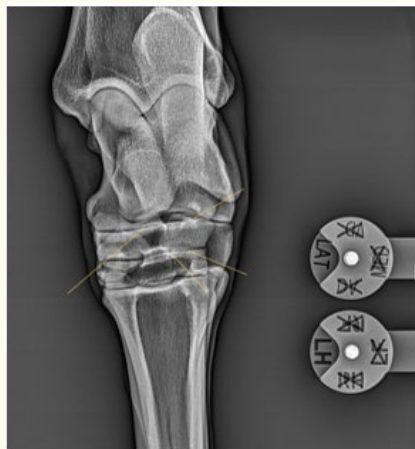

Figure 4: Radiographic image of the standardbred indicating arthritis in the left hock.

Statistics (internal)

The distribution of sole thickness satisfied the normality assumption for each internal sole location of horses and ponies (Table 1). Consequently, a paired samples t-test (parametric test) was employed to compare mean internal sole thickness before and after the 50-km walk intervention. P-values from the Shapiro-Wilk test exceeded 0.05 for internal measurements in both horses and ponies, indicating significant growth.

	(Horses)			(Ponies)		
	Statistic	df	P-value	Statistic	df	P-value
Crena (Before)	0.95	8	0.731	0.92	8	0.428
PP (Before)	0.95	8	0.695	0.98	8	0.966
Crena (After)	0.91	8	0.369	0.94	8	0.563
PP (After)	0.90	8	0.268	0.90	8	0.302

Table 1: Normality test for internal measurements (sole depth) in horses and ponies.

Table 1 displays the Shapiro-Wilk p-values indicating sole growth in eleven hooves of all animals, at one or both anatomical sites measured.

		Mean	Sample Size	Std. Deviation	P-value
Crena	Before	14.88	8	4.09	0.334
	After	14.63	8	3.11	
PP	Before	20.75	8	2.55	0.343
	After	21.38	8	3.74	

Table 2: Paired t-test results for internal measurements (sole depth) in horses.

Table 2 illustrates the impact of the 50-km walk intervention on horses, indicating negligible changes in crena and PP sole depth. A marginal reduction at crena (mean difference: 0.25 mm) suggests slight wear, while an overall increase at the PP site (mean difference: 0.63 mm) indicates growth.

		Mean	Sample Size	Std. Deviation	P-value
Crena	Before	14.75	8	1.49	0.071
	After	14.00	8	1.69	
PP	Before	22.25	8	2.82	0.013
	After	24.25	8	3.99	

Table 3: Paired t-test results for internal measurements (sole depth) in ponies.

Table 3 outlines the effects of the 50-km walk intervention on ponies, revealing negligible changes in crena and a significant increment in PP. A general reduction at crena (mean difference: 0.75 mm) suggests slightly more wear compared to the horses, whereas an overall increase at the PP (mean difference: 2 mm), indicates growth.

External measurements

In the CG measurements at the mid-bar, horses experienced a slight increase, whereas ponies experienced a reduction of a few millimeters. The CG depth at the apex decreased in horses but increased in most pony hooves. The coronet-toe distance decreased or remained unchanged in all equines. Frog apex-toe measurements were slightly reduced in most hooves. Frog width varied across the animals, either increasing or decreasing by a few millimeters. Heel height in both horses and ponies increased in eight hooves.

No visible pathologies were observed in any of the outer hoof capsules. Frogs and soles were dry, hard, and calloused in all equines. Exfoliation occurred at the frog site of some hooves. Hoof wall growth was more apparent in all feet by day 9 after 36 km than by day 18, after 14 km (Figure 5 and 6). Measurements were insignificant at 14 km. Since the hoof walls of all equines had grown by day 9 and were no longer level with the sole, they were trimmed. At the end of the study, small areas of the hoof wall were chipped at the quarters of three horse hooves. All hooves had natural concavity, although this was more pronounced in the horses’ forefeet. Bar growth was visible in the forefeet of both horses and one pony. No equines showed signs of lameness or sensitivity. The Standardbred had a negative plantar angle in the LH, revealed in the follow up radiographs (See figure 3, 4 and 7).



Figure 5: Solar view of the left front hoof (of each animal) on day 1 and day 9, after covering a 36-km distance.



Figure 6: Solar view of the left front hoof (of each animal) on day 10 and day 18, after 14 km.



Figure 7: Left front hoof of the Standardbred with a negative plantar angle (See radiograph in figure 3).

Statistics (external)

Hoof growth distribution satisfied the normality assumption for each external anatomical location of horses and ponies. Thus, paired-samples t-tests (parametric test) were used to compare the mean external hoof growth before and after the 36-km walk.

	(Horses)			(Ponies)		
	Statistic	df	P-value	Statistic	df	P-value
Frog apex-toe (Before)	0.86	8	0.110	0.95	8	0.751
CG depth mid-bar (Before)	0.91	8	0.361	0.90	8	0.286
CG depth apex (Before)	0.91	8	0.378	0.86	8	0.101
Heel height (Before)	0.90	8	0.267	0.92	8	0.408
Frog width (Before)	0.96	8	0.881	0.86	8	0.129
Coronet-toe (Before)	0.97	8	0.908	0.89	8	0.223
Frog apex-toe (After)	0.87	8	0.152	0.85	8	0.108
CG depth mid-bar (After)	0.92	8	0.494	0.92	8	0.397
CG depth apex (After)	0.86	8	0.122	0.86	8	0.116
Heel height (After)	0.91	8	0.366	0.86	8	0.135
Frog width (After)	0.86	8	0.130	0.93	8	0.489
Coronet-toe (After)	0.97	8	0.873	0.88	8	0.206

Table 4: Normality test for external measurements in horses and ponies.

Table 4 presents the Shapiro-Wilk test-derived p-values for the normality test conducted on external measurements in the equines following the 36-km walk. Values exceeding 0.05 indicate growth in the measured parameters.

		Mean	Sample Size	Std. Deviation	P-value
Frog apex-toe	Before	3.63	8	0.49	0.003
	After	2.85	8	0.45	
CG depth mid-bar	Before	1.71	8	0.39	0.334
	After	1.90	8	0.15	
CG depth apex	Before	0.93	8	0.09	0.598
	After	0.90	8	0.17	
Heel height	Before	3.61	8	0.29	0.031
	After	3.19	8	0.53	
Frog width	Before	6.05	8	0.62	< 0.001
	After	3.70	8	0.53	
Coronet-toe	Before	7.85	8	0.40	< 0.001
	After	5.28	8	0.76	

Table 5: Effects of the 36-km walk on hoof measurements in horses.

Table 5 illustrates the impact of the 36-km walk intervention on hoof measurements for horses, resulting in a significant reduction in frog apex-toe, coronet-toe (dorsal), and frog width. Mean heel height was reduced by 0.40 cm. Negligible impact was observed on the CG depth at mid-bar and CG depth at apex.

		Mean	Sample Size	Std. Deviation	P-value
Frog apex-toe	Before	3.61	8	0.62	0.005
	After	2.89	8	0.49	
CG depth mid-bar	Before	1.98	8	0.36	0.103
	After	1.73	8	0.18	
CG depth apex	Before	0.53	8	0.16	<0.001
	After	1.02	8	0.07	
Heel height	Before	3.63	8	0.52	0.112
	After	3.33	8	0.49	
Frog width	Before	5.83	8	1.15	0.003
	After	3.83	8	0.48	
Coronet-toe	Before	7.59	8	0.49	<0.001
	After	5.09	8	0.87	

Table 6: Effects of the 36-km walk on hoof measurements in ponies.

Table 6 demonstrates the consequences of the 36-kilometre walk intervention on hoof measurements for ponies, with a significant reduction in the distance at the solar surface between the frog apex-toe (Figure 8), coronet-toe (dorsal), and frog width (indicating wear). A significant increase was observed in CG depth at the apex (indicating growth), whereas changes in the CG depth mid-bar and heel height were negligible.

Discussion

The outcomes of the present study were counterintuitive. Despite the development of hardened soles, the unexpected findings included hoof wall trimming on day 9, phalangeal misalignment, and sole growth. In the radiographs, sole thickness was more noticeable at the PP in eleven hooves, yet external measurements presented an increase in heel height in eight feet of both horses and ponies. Bellenzani, *et al.* [11] observed barefoot horses exercising on a treadmill for four weeks at different gaits, reporting higher heels; however, they did not explain the observed PP growth. In our study, the horses exhibited a more pronounced, natural concavity in the front hooves, confirming a thicker sole depth at the apex, evident in radiographs. Most external measurements from the coronet-toe were shorter in both horses and ponies, suggesting wear at the toes during the breakover phase, on abrasive surfaces. Frog apex-toe measurements indicated decreased distances in all equines, signifying wear at the toes (Figure 8).




Figure 8: External measurements recorded from solar and dorsal sites.

Accelerated hoof wall growth became evident in the outer hoof capsules after covering 36 km. An hour of walking per day (4 km) on abrasive surfaces may not sufficiently wear away the hoof wall. However, our results emphasize the importance of short trimming cycles of no longer than three weeks. Follow-up radiographs revealed misaligned phalanges in four hooves after the 50-km walk. These animals are maintained on a regular 2 - 3-week trimming cycle to minimize hoof wall loading and sustain balance. Although literature highlights the importance of short trimming cycles in horses, especially those with hoof pathology [4], practices in the UK often utilize 6 - 8 week trimming cycles, for both shod and barefoot horses [31]; however, there is no information on phalangeal misalignment. Kummer, *et al.* [32] reported regular, shoeing cycles of 8 - 10 weeks but did not provide any information on palmar/plantar angles or mediolateral imbalance. Further studies are required to explore misalignment and mediolateral imbalances during extended trimming cycles. While our findings highlight the benefits of shorter trimming cycles, hoof wall growth must be examined in a larger population of barefoot-kept horses. To date, the effects of climate, housing conditions, diet, and exercise surface on hoof wall growth has not been documented.

A comprehensive investigation was essential to examine accelerated sole growth, given the limited information in equine veterinary literature, particularly owing to the constraints of conventional radiography in visualising soft tissue. Scientific studies indicate that the hoof serves as a neurosensory organ, rich in sensory nerves with various fiber types and neurotransmitters, transmitting information to the central nervous system [13]. These neurotransmitters act as receptors processing environmental stimuli [13], mirroring functions observed in the human foot [33]. Microscopic examination of internal hoof anatomy reveals Pacinian corpuscles (mechanoreceptors) abundant in the caudal part of the foot, potentially influencing vascular changes [34]. They require constantly changing stimuli, respond to pressure and vibration, and are crucial in the gait cycle of a horse. Since these corpuscles are scant in the toe region or corium, this indicates that the horse is a rear-foot striker [13]. However, the effects of these corpuscles on sole depth in horses walking over hard surfaces have not been investigated. In humans, Pacinian corpuscles are tightly grouped in various soft tissues around the metatarsal pad and proximal phalanges [15]. These FA2s are higher in number than other receptor-types located in the foot [14] and may suggest that humans are foot-first strikers when running and jumping, landing first on their foot pads to minimize impact and dampen the ground reaction forces (GRFs) [35]. Sole growth was more prominent at the PP of the animals used in the study.

Given that most Pacinian corpuscles are located at the caudal part of the hoof, respond to high-frequency vibrations and rapidly adapt to pressure and stimuli [13], growth in this area was accelerated as it constituted a primary impact point on hard surfaces. A study conducted on individuals in Western Kenya who were habitually barefoot, revealed thicker calluses at the metatarsal head than at the heel [14], suggesting a parallel function of FA2s upon impact. Here, the solar side of the foot produces calluses through environmental stimuli, simultaneously protecting against injury [35].

Conversely, when assessing sole depth in the hooves of Sable Island and Kaimanawa feral horses, they appeared thin, both at the crena and PP, irrespective of overgrown hoof walls. Pacinian corpuscles in this scenario, might perceive or detect less pressure and vibration owing to the tendency of the soft ground to muffle, or mute, impacted vibrations. Furthermore, chronic exposure to soft surfaces could render FA2s less responsive or cause them to atrophy, both of which could lead to reduced afferent activity from the GRF. Additional studies are imperative to explore this phenomenon of thicker sole depths on harder surfaces, independent of hoof wall condition. The potential role of the somatosensory system in modulating changes in the equine foot on different terrains necessitates further investigation.

Ventral to the distal phalanx, sole thickness, as seen radiographically, consists of an internal and external zone of the dermis and keratinized epidermis, respectively. The dermal zone is composed of a microvasculature system, matrix tissues, including elastic and reticular fibers, fascial sheets, and cords along with isolated small clusters of adipocytes. The external layer, composed of epidermal tubules and the intertubular horn, closely adheres to this dermal configuration. Collectively, these elements gradually arch across the width of the foot, between the toe and dorsal third of the frog, whereas caudally, a greater arch of the sole slants toward the epidermal bars juxtaposed near the midline. This complex arrangement, functions as a unique unit, supporting energy dissipation, regenerative

capabilities of the solar foot, and directing energy impact forces toward appropriate tissues, including limb loading of the bony column. Within the dermis, a dense microvasculature concentrated at its solar margins and caudally ventral to the palmar processes [36], serves as a loading site along the peripheral sole, simultaneously contributing to these functions. These two solar layers, either together or alone, may have contributed to the increased sole thickness in horses and ponies walking on the road. This distinctive structural arrangement of solar tissues between the distal phalanx and varied terrain features, highlights the need for further investigation in both of these areas.

The digital cushion (DC) is a wedge-shaped fibrous and fibrocartilage tissue located proximal to the frog, encompassing much of the caudal part of the foot. It plays a critical role in the hoof, buffering high-impact forces in the limbs [37,38]. This particular structure absorbs GRFs during heel-first landings, dissipates energy and rebounds back into its shape as the heel is lifted [38]. Notably, the DC harbors the most neuroreceptors in the foot [13]. When the frog makes contact with the ground, the DC can receive adequate stimuli, encouraging the development of fibrocartilage [38,39]. Thus, the DC may have also contributed to the observed sole thickness in the hooves of the animals in this study. Further investigations could measure digital cushion thickness to confirm this, employing digital sonography, as previously conducted on bovines [40]. Additionally, considering that the forelimbs of equines support 60% of their body weight, it is plausible that they would possess thicker digital cushions than the hind feet, as documented in bovines [40].

Load distribution within the equine feet holds paramount importance for locomotion. Trimming techniques should ensure or enhance an even distribution of load among the hoof wall, sole, frog, and bars [4], with a focus on maintaining short toes to maximize breakover and facilitate heel-first landings. In a well-balanced foot, internal and external structures synergize, fostering compliance, over uneven surfaces. A study on elephants demonstrated that the DC aids in distributing load evenly within the sole, effectively buffering impact forces [41]. Similar emphasis on the significance and role of a healthy DC has been noted in studies on confined dairy cows [40,42,43]. Nonetheless, we acknowledge that horses did not evolve to roam over artificial surfaces. Instead, their evolution is tailored to terrains, allowing dirt (earth) packs underneath their hooves, facilitating central limb loading and even energy dissipation [44,45].

Internally, a well-balanced hoof aligns all three phalanges [32], with palmar or plantar angles varying between 3 - 5 degrees [3]. In follow-up radiographs of the horses in this study, internal sole thickness at the crena ranged between 11 - 15 mm (mean: 13 mm) in the forefeet with no signs of lameness or sensitivity, especially on gravel. A similar observation applied to ponies, exhibiting a slightly thicker sole, ranging between 14 - 16 mm (mean: 15 mm) in the forefeet, at the same anatomical site. Despite the ponies covering more paces owing to their shorter stride throughout the 50 km distance, they displayed thicker soles at the crena. Thick soles, as evidenced in this study, are associated with healthy hooves [6]. However, broader studies on a larger cohort of barefoot-kept horses are essential to establish a standard optimal sole depth for various surface types. In a well-developed foot, the lateral cartilages should constitute no less than one-third of the total length from the crena to the heel [4,44], indicating that the larger the area at the caudal part of the foot as observed in radiographs, the healthier. This is evident in the feet of all equines used in the study, hence promoting sole growth. Figure 9 illustrates a radiograph of the Standardbred's foot.

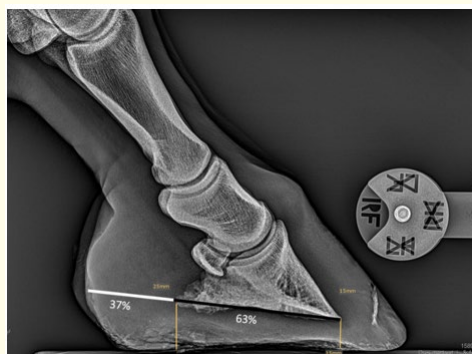

Figure 9: Lateral view of the caudal foot area, slightly over a third in length relative to P3 length, indicating well-developed, lateral cartilages.

Nutrition significantly influences the health and welfare of horses, including their soles [4,45,46]. Additionally, a high sugar-starch diet has long-term implications for hoof health [9,47,48]. Podiatry studies over the last two decades, emphasize the importance of a forage-based diet for optimal hoof health. However, references to this diet predominantly pertain to rehabilitation cases, given that hoof issues often have metabolic origins [4,16]. Anecdotal information suggests that many barefoot-kept horses without hoof problems are transitioning to 100% forage-based diets, consisting of good quality hay (tested for nutrients) and replacing grain or pelleted feed with forage balancers [31], based on the National Research Council recommendations [49]. These balancers, supplied in powdered form, contain minerals (and some vitamins) typically deficient in hay [50]. A forage-based diet could be a contributing factor to the intact and distortion-free hooves observed in the animals from this study.

Effective management plays a crucial role in sustaining healthy soles. Barefoot-kept horses benefit from exposure to both hard and soft ground. The more varied the terrain, the more conditioned and resilient their hooves become. The equines included in this study were predominantly outdoors, mainly on compacted soil and grassland (rocky steppe) with minimal green grass. Despite covering a distance of 50 km on hard ground, this exercise may prove less advantageous for their limbs in the long term, especially for horses with arthritis (See figure 3, 4 and 7) given the heightened concussion absorbed during impact on firm surfaces [51,52]. The GRF might predispose them to soft tissue injuries and degenerative joint disease [52], unless their feet are shielded by dampening products such as hoof boots. Conversely, brief periods of road walking could offer benefits during the shod-to-barefoot transition phase, potentially accelerating the process to increase sole thickness, as demonstrated in this study.

While the horses and ponies in this investigation were hand-walked over abrasive surfaces, we hypothesized that hoof morphology would exhibit minimal variation even if they were ridden. Feral herds traversing several kilometers over challenging terrains, including pregnant mares [53] that undergo a 15% increase in body weight during the final trimester [54], with foals weighing around 52 kg at birth [55], do not experience physical handicaps owing to excess weight, and their hooves remain unaffected.

Conclusion

Scientific data on the hoof performance of domesticated, barefoot-kept horses and ponies on tarmac, gravel and concrete screed is limited. Counterintuitively, observed sole growth after the 50 km walk, was consistent across breeds, ages, and sexes. Collectively, our findings have provided novel insights into the ability of the somatosensory system in equines.

Nevertheless, further research is warranted to overcome a few limitations in this study. The artificial surfaces that the hooves were exposed to could be explored in terms of distance and gait, particularly considering the rapid hoof wall growth within nine days. Proprioceptive abilities prompted sole growth at both anatomical sites of the coffin bone, with accelerated growth at the PP. Increased density and thickness in the solar dermis and digital cushion may have contributed to greater sole depth, which is evident in radiographs. Examining the keratinized epidermis of the sole in relation to FA2 ability and growth, as in studies on human and animal feet, is a potential avenue for exploration. Misaligned phalanges and hoof wall growth after 36 km, highlight the importance of frequent trimming cycles. In regard to sole depth, the results lay a foundation for establishing an optimal standard thickness in barefoot-kept horses and ponies housed or exercised on specific terrains. Consistent with existing literature, our findings suggest that hoof wall exhibits growth independent of ground type; however, sole thickness is terrain-dependent, being thicker on harder surfaces and thinner on softer surfaces. In summary, three presumed contributing factors to the findings include forage-based diets, continuous turnout, and frequent, non-invasive trimming cycles. Nonetheless, additional research is warranted to comprehensively elucidate the influence of these factors on hoof health.

Disclosure Statement

The authors declare no potential conflicts. Ms. Sarah Albanozzo, an independent researcher, designed and implemented the radiological study, interpreted the data and drafted the article. Dr. Louis Borg, an equine veterinarian, examined the horses, and recorded

all radiographs and internal measurements. Prof. Liberato Camilleri, a statistician, performed the statistical analyses and assisted with data interpretation. Prof. Robert M. Bowker, an equine veterinarian and neurobiologist, assisted in the interpretation of results and contributed to this article.

Funding Support

This research received no external funding.

Acknowledgements

We acknowledge the assistance of Marta Szpalerska and Michael Albanozzo.

Bibliography

1. Parks AH. "Anatomy and function of the equine digit". *Equine laminitis* (2017): 13-21.
2. Grundmann INM., *et al.* "Quantitative assessment of the equine hoof using digital radiography and magnetic resonance imaging". *Equine Veterinary Journal* 47.5 (2015): 542-547.
3. Redden RF. "Hoof capsule distortion: understanding the mechanisms as a basis for rational management". *Veterinary Clinics: Equine Practice* 19.2 (2003): 443-462.
4. Ramey P. "Care and Rehabilitation of the Equine Foot". Hoof Rehabilitation Publishing, LLC (2011): 74-78, 135-150, 195, 285, 287, 293, 345-346, 393, 404.
5. Taylor D., *et al.* "Clinical outcome of 14 obese, laminitic horses managed with the same rehabilitation protocol". *Journal of Equine Veterinary Science* 34.4 (2014): 556-564.
6. Mellish MA., *et al.* "An estimation of lameness in Sable Island horses using radiographic evaluation of the distal phalanx and hoof capsule". *Journal of Applied Animal Welfare Science* 26.2 (2023): 184-194.
7. Hampson BA., *et al.* "Morphometry and abnormalities of the feet of Kaimanawa feral horses in New Zealand". *Australian Veterinary Journal* 88.4 (2010): 124-131.
8. Clayton HM., *et al.* "Effects of barefoot trimming on hoof morphology". *Australian Veterinary Journal* 89.8 (2011): 305-311.
9. Stewart J. "Understanding the Horse's Feet". The Crowood Press Ltd (2013): 61, 102, 124.
10. Dorner C., *et al.* "Relationship between the distal phalanx angle and radiographic changes in the navicular bone of horses: A radiological study". *Global Journal of Medical Research* 17.2 (2017): 7-13.
11. Bellenzani MC., *et al.* "Investigation of forelimb hoof wall strains and hoof shape in unshod horses exercised on a treadmill at various speeds and gaits". *American Journal of Veterinary Research* 73.11 (2012): 1735-1741.
12. Bowker RM., *et al.* "Sensory receptors in the equine foot". *American Journal of Veterinary Research* 54.11 (1993): 1840-1840.
13. Bowker RM., *et al.* "The Horse's foot as a neurosensory organ: how the horse perceives its environment". *Care and Rehabilitation of the Equine Foot* (2011): 98-133.
14. Holowka NB., *et al.* "Foot callus thickness does not trade off protection for tactile sensitivity during walking". *Nature* 571.7764 (2019): 261-264.

15. Germann C., *et al.* "Novel observations of Pacinian corpuscle distribution in the hands and feet based on high-resolution 7-T MRI in healthy volunteers". *Skeletal Radiology* 50.6 (2021): 1249-1255.
16. Geor RJ. "Metabolic predispositions to laminitis in horses and ponies: obesity, insulin resistance and metabolic syndromes". *Journal of Equine Veterinary Science* 28.12 (2008): 753-759.
17. van Eps A. "General clinical aspects of the laminitis case". *Equine Laminitis* (2017): 181-190.
18. Holmes TQ and Brown AF. "Champing at the bit for improvements: A review of equine welfare in equestrian sports in the United Kingdom". *Animals* 12.9 (2022): 1186.
19. Bras R and Morrison S. "Mechanical principles of the equine foot". *Veterinary Clinics: Equine Practice* 37.3 (2021): 581-618.
20. O'Grady Stephen E. "Various aspects of barefoot methodology relevant to farriery in equine veterinary practice". *Equine Veterinary Education* 28.6 (2016): 321-326.
21. Cook WR. "Metal, myth and equine misery". *Animal Welfare Science, Ethics and Law Veterinary Association Journal* (2008).
22. Proske DK., *et al.* "Effects of barefoot trimming and shoeing on the joints of the lower forelimb and hoof morphology of mature horses". *The Professional Animal Scientist* 33.4 (2017): 483-489.
23. Tocci R., *et al.* "Hoof quality of Anglo-Arabian and Haflinger horses". *Journal of Veterinary Research* 61.3 (2017): 367-373.
24. Jackson J. "The Natural Trim: Principles and Practices". J. Jackson Publishing (2019): 85-88.
25. Dittmann MT., *et al.* "Husbandry, use, and orthopedic health of horses owned by competitive and leisure riders in Switzerland". *Journal of Equine Veterinary Science* 91 (2020): 103107.
26. Smith R., *et al.* "A qualitative exploration of UK leisure horse owners' perceptions of equine wellbeing". *Animals* 12.21 (2022): 2937.
27. Denny JT. "Horses and roads or, how to keep a horse sound on his legs: being a series of papers republished from "The Farm Journal"". Longmans, Green (1880): 83, 85-90, 94-95, 98.
28. Fleming G. "Horse-Shoes and Horse-Shoeing". Chapman and Hall, London (1869): 7-11.
29. Baker I. "Fifty materials that make the world". Springer (2018): 11-13.
30. Animal Welfare Act, Chapter 439 (2002).
31. Beale S. "Keeping horses barefoot: a shared accomplishment". The University of Liverpool (United Kingdom) (2021): 106-107, 193.
32. Kummer M., *et al.* "The effect of hoof trimming on radiographic measurements of the front feet of normal Warmblood horses". *The Veterinary Journal* 172.1 (2006): 58-66.
33. Schlee G., *et al.* "Effects of footwear on plantar foot sensitivity: a study with Formula 1 shoes". *European Journal of Applied Physiology* 106.2 (2009): 305-309.
34. Bowker RM., *et al.* "Morphological evaluation of Merkel cells and small lamellated sensory receptors in the equine foot". *American Journal of Veterinary Research* 78.6 (2016): 659-667.
35. Lieberman DE. "What we can learn about running from barefoot running: an evolutionary medical perspective". *Exercise and Sport Sciences Reviews* 40.2 (2012): 63-72.

36. Schade SM., *et al.* "The microvasculature in the equine distal phalanx: implications for fracture healing". *Veterinary and Comparative Orthopaedics and Traumatology* 27.2 (2014): 102-106.
37. Getty R. "The Sisson and Grossman's the Anatomy of the Domestic Animals". Volume 1, 5th edition. W.B. Saunders Company, Philadelphia (1975): 729-735.
38. Bowker RM. "Contrasting structural morphologies of 'good' and 'bad' footed horses". *Proceedings American Association of Equine Practitioners* 49 (2003): 186-209.
39. Bowker Robert M. "The vascular cushion of the frog: avoiding consequences of laminitis through an understanding of fascia, microvessels, and dissipation of energy" (2017).
40. Stambuk CR., *et al.* "A longitudinal study of digital cushion thickness and its function as a predictor for compromised locomotion and hoof lesions in Holstein cows". *Translational Animal Science* 3.1 (2019): 74-83.
41. Ramsay EC and Henry RW. "Anatomy of the elephant foot". In *The Elephant's Foot* (eds Csuti B, Sargent EL, Bechert US). Ames, IA: Iowa State University Press (2001): 9-12.
42. Råber M., *et al.* "The bovine digital cushion—a descriptive anatomical study". *The Veterinary Journal* 167.3 (2004): 258-264.
43. İzci C., *et al.* "Histochemical and histomorphometrical studies on the digital cushion of heifers and dairy cows with claw horn lesions". *Concepts of Dairy and Veterinary Sciences* 3 (2019): 254-262.
44. Bowker RM. "Understanding Laminitis: How We View "Normal" Function" (2017).
45. Teskey T. "Insight to Equus". Tomas G Teskey and Csenge Z. Bakos Publishing (2021): 73, 80-83.
46. Harris PA., *et al.* "Feeding conserved forage to horses: recent advances and recommendations". *Animal* 11.6 (2017): 958-967.
47. Stonebridge A and Cumberlidge J. "Barefoot Horsekeeping". The Crowood Press Ltd (2016): 91.
48. Potter SJ., *et al.* "Incidence of laminitis and survey of dietary and management practices in pleasure horses and ponies in south-eastern Australia". *Australian Veterinary Journal* 95.10 (2017): 370-374.
49. Pagan, JD. "NRC releases horse revisions: the National Research Council equine committee reviewed literature on equine nutrition and compiled a very useful and practical document for calculating nutrient requirements for various classes of horses". *Feedstuffs* 79.18 (2007): 12-14.
50. ForagePlus Ltd.
51. Hanley J. Elastomeric hoof boots (2003): 160, 170.
52. Crevier-Denoix N., *et al.* "Effect of track surface firmness on the development of musculoskeletal injuries in French Trotters during four months of harness race training". *American Journal of Veterinary Research* 78.11 (2017): 1293-1304.
53. Reed C. "Nussbaum's capabilities approach to compassionate conservation: the case of wild horses in the United States". *Society and Animals* 1 (2021): 1-15.
54. Lawrence LM., *et al.* "Changes in body weight and condition of gestating mares". *Journal of Equine Veterinary Science* 12.6 (1992): 355-358.
55. Klewitz J., *et al.* "Effects of age, parity, and pregnancy abnormalities on foal birth weight and uterine blood flow in the mare". *Theriogenology* 83.4 (2015): 721-729.

Volume 9 Issue 1 January 2024

©All rights reserved by Sarah Albanozzo., *et al.*

Citation: Sarah Albanozzo., *et al.* "Hoof Capability of Barefoot-Kept Horses and Ponies Walking Over Artificial Environments: An Anatomical and Radiological Study. *EC Veterinary Science* 9.1 (2024): 01-15.